

CASE REPORT

Molar Pregnancy with a co-exist Normal Viable Fetus and Successful Pregnancy Outcome: A Case Report

Nasrin Hossain^{1*}, Faria Anjuman², Mohammad Sharif Mahmud³, Shamin Hossain⁴

¹Department of Gynaecological Oncology, National Institute of Cancer Research and Hospital (NICRH), Dhaka, Bangladesh; ²Department of Pathology, Sir Salimullah Medical College, Dhaka, Bangladesh; ³Combined Military Hospital (CMH), Dhaka, Bangladesh; ⁴Department of Gynae & Obstetrics, Shahid Ahsanullah Master General Hospital, Dhaka, Bangladesh.

Abstract

Background: Co-existence of a hydatidiform mole with a normal fetus is extremely rare and is considered as a high risk pregnancy.

Methods: It was an observational study conducted during July 2020 to march 2021

Case report: A 23 year old primigravida, referred with a diagnosis of 27 weeks pregnancy with gestational choriocarcinoma. She was a booked patient. USG report at 9 weeks with a single gestational sac and single fetal pole. Her complains were lower abdominal pain and brownish vaginal discharge. Serum Beta HCG was 3,23,280 IU/L. USG and fetal MRI report were single gravied fetus, no anomaly detected and a large hyper echogenic soft tissue mass (10*7cm) interposed with multiple tiny cystic spaces near to placenta. Diagnosis was 28 weeks pregnancy with partial mole and high rising β HCG level. Thoroughly evaluated the patient to exclude distal metastasis. Proper counseling, the pregnancy was continued as per the patient's desire. The pregnancy was closely monitored with serial serum β HCG and USG. Spontaneously labour pain start at 36 weeks pregnancy and delivered a live baby per vaginally at 36 weeks with near normal Apgar score. The placenta with molar tissue was sent for histopathological examination. The histopathologically confirmed partial mole with normal placenta. Beta HCG was 20,000 ml/L at 7 days and normal at 8 weeks after delivery. Close surveillance for 6 months. After 6 month follow-up, both mother and development of her baby are alright.

Conclusion: The diagnosis, management and monitoring of this condition will remain challenging because of its rarity. Though the general trend is to terminate pregnancy with coexistent mole in anticipation of complications, under close surveillance, optimal outcomes can be achieved.

Keyword: Molar pregnancy, co-exist normal viable fetus, successful pregnancy

Introduction

The co-existence of a hydatidiform mole with a normal fetus is extremely rare and is considered as a high risk pregnancy.¹ The incidence of complete hydatidiform mole co-existing live fetus and partial mole with co-existing live fetus is 1/20,000 to 1/1,00,000¹ and 1/10,000 to 1/20,000² respectively. Hydatidiform mole is a part of a group of genetically abnormal conceptions named gestational trophoblastic disease. The condition is normally benign, with a variable potentially risk of becoming malignant. According to histopathology and microscopic features of the placenta, moles are classified into complete and partial mole.³

The coincidence of molar changes with a normal fetus poses several risk to the mother and fetus.⁴ There is a controversy regarding whether it is better to terminate the pregnancy or follow the mother until a normal delivery. Due to the life-threatening complications of this condition, including massive bleeding, hyperthyroidism, pre-eclampsia and trophoblastic diseases, termination of pregnancy is usually preferred.⁵ Here, we present the case of a singleton pregnancy that showed molar changes in pathological study of placenta and ended up with a normal viable neonate.

Case report

Mrs. Sanjida, a 20 year old primigravida referred to Gynecological Oncology Department of National Institute of Cancer Research and Hospital (NICRH), Dhaka with a diagnosis of 27 weeks pregnancy with gestational choriocarcinoma. Her complains were abdominal pain and vaginal spotting for 2 weeks. She was on regular antenatal care. Routine USG were done

***Correspondence:** Nasrin Hossain, Department of Gynaecological Oncology, National Institute of Cancer Research and Hospital (NICRH), Dhaka, Bangladesh.

Email: nasrinhossain23@gmail.com

ORCID: 0000-0002-0467-434x

at 9 weeks and 18 weeks pregnancy; report were normal. At 27 weeks, ultrasonography and β HCG was done outside NICRH in private chamber report was 27 weeks pregnancy with suggestive of hydatidiform mole; N.B: a large hyper echogenic soft tissue mass interposed with multiple tiny cystic spaces is seen in the cavity near to placenta size about 9.3x9.6 cm and serum β HCG was 3, 23,280 IU/L at 7months pregnancy (but normal value 3000-15000 IU/L).

On examination the patient was mildly anemic, other vital signs were normal. Per abdominal examination revealed fundal height slightly more according to her gestation. Abdomen was soft, non-tender, fetal movement normal & FHR 146 b/m. On speculum examination slight brownish discharge come out from cervix. Then the case was thoroughly evaluated

including all blood tests and fetal MRI. Fetal MRI report was; uterus gravid with single fetus, no anomaly was detected. Pregnancy related structures; a fairly large lesion (10x7 cm) made of T_2 hyper intensity thin walled tiny cystic structures seen in right anterior-lateral aspect of amniotic cavity close to lateral margins of placenta. Comment; suggestive of partial mole/co-exist molar pregnancy with a viable fetus. Serum β HCG was 1, 97,690 IU/L. All blood tests report were normal. Chest X-ray was not done because of asymptomatic patient and concern regarding safety of ray exposure.

Proper counseling was given to the patient and party, about the risk of continuing the pregnancy or termination of pregnancy. Also discussed about complication of this pregnancy. Patient willingly wanted to continue the pregnancy up to term pregnancy after knowing all

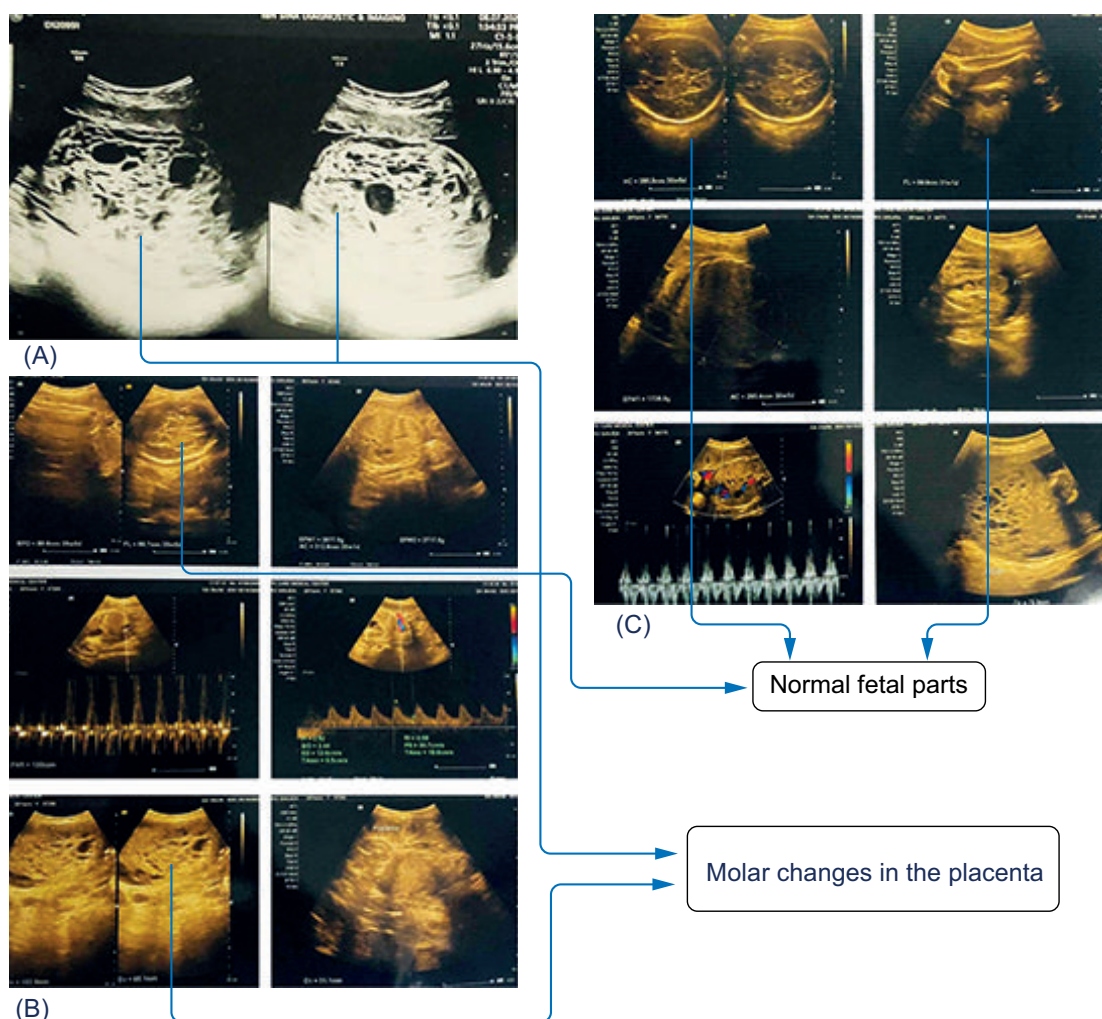


Figure 1: A) At 27 weeks pregnancy with suggestive molar pregnancy B) USG at 31 weeks pregnancy with molar pregnancy C) USG at 35 weeks pregnancy with alive fetus and co-exist molar pregnancy.

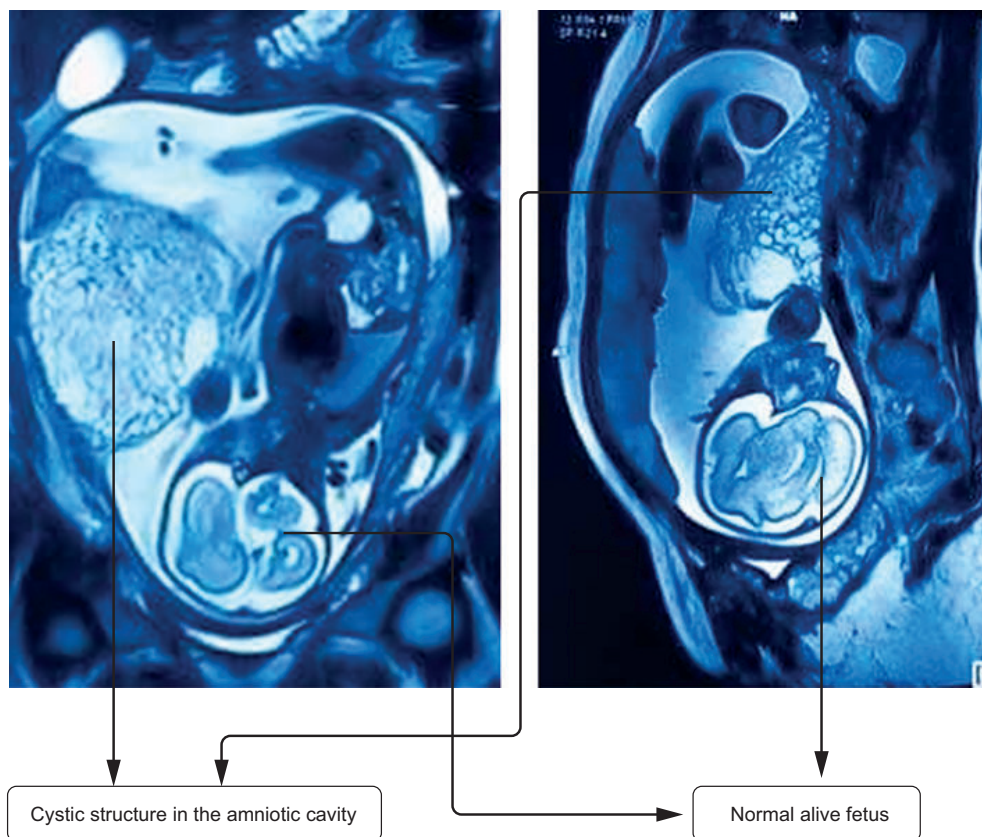


Figure 2: A) Sagittal view B) coronal view of fetal MRI at 28 weeks pregnancy.

consequence of the disease. She was under close follow up. During every visit patient was examined and serum β HCG weekly, USG of pregnancy profile every 3-4 weeks interval. Serial β HCG were 1,18,087 and 2,79,480 IU/L on two consecutive weeks. No complication developed during her antenatal checkup except slight PV bleeding.

At her 36 weeks pregnancy, she was admitted in hospital with labour pain and delivered a male baby, weight 2.4kg. Her labour was uneventful. Placenta was sent for histopathology and report was confirm partial molar pregnancy. Serum β HCG was done at 7 days after delivery report 20,000 IU/L.

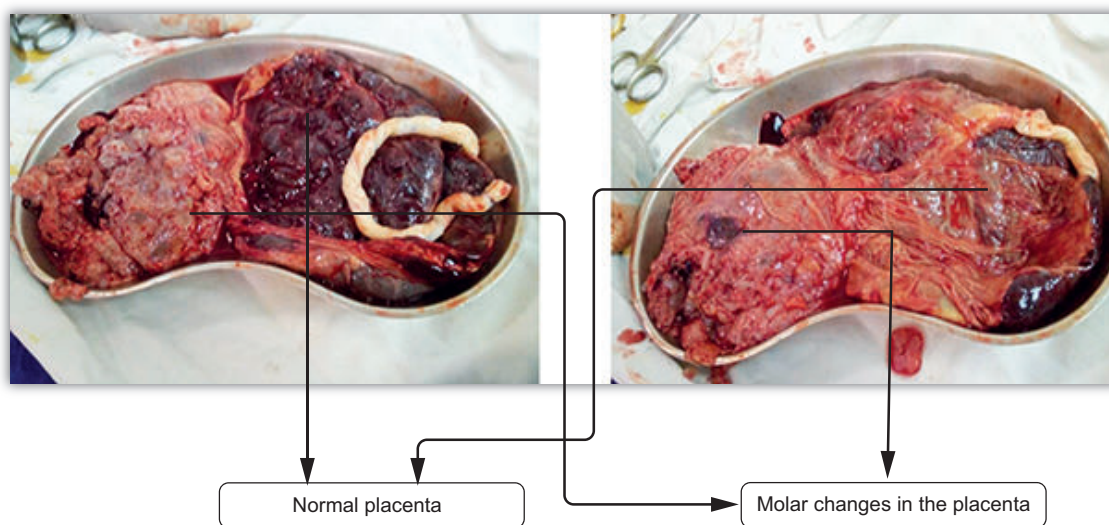


Figure 3: Normal placenta with partial molar changes (<50%)

Subsequent follow-up of the patient for 6 months up to March, 2021. Her serum β HCG was normal limit after 2 months of delivery. According to the statement of the mother, development of baby was normal up to 6 months of his age.

Discussion

Gestational trophoblastic disease constitutes a diverse group which comprises lesions that include abnormally placenta (hydatidiform moles), benign tumor like lesion and trophoblastic neoplasm.⁴ In partial molar pregnancy, there is usually an abnormal fetus with triploid genotype that is associated with a large placenta showing cystic changes.⁴

The incidence of such normal diploid fetus associated with partial molar placenta is extremely rare. Here we report a case of partial molar pregnancy in which a normal pregnancy with a normal appearing fetus was found to coexist. Partial molar pregnancy with co-existing alive pregnancy has an incidence of 0.005 to 0.01% of all pregnancies.¹ It is usually derived from union of a haploid normal oocyte with two sperms, leading to dispermic fertilization and producing a triploid set of chromosome.⁴

There are two distinct entities in the ultrasound finding of a live fetus with molar changes in the placenta. It could be either a dizygotic gestation with one complete molar or partial molar pregnancy along with co-existing live fetus having a normal karyotype attached to a normal placenta, or it could be a singleton partial mole with a dysmorphic fetus and abnormal karyotype (mostly triploid). These two conditions have different genetic etiologies and outcomes, thus need to be primary ultrasound detection. Prenatal diagnosis can be done by amniocentesis to rule out triploidy or any other genetic abnormality before advising the continuation of pregnancy.⁵

In our reported case, USG was done during 9+ weeks and 18+ weeks pregnancy and reports were normal alive fetus with normal appearing placenta. The present case, molar pregnancy was first suspected as late as 27 weeks of gestation. At present, an USG examination is the main imaging tool used to establish the diagnosis. The Swiss-cheese pattern placenta separate from a normal-appearing placenta is pathognomic.⁶ Since the prognosis for pregnancy outcome is different in each case, visualization of normal placenta often adjacent to large molar placenta is of key importance for correct diagnosis. The

differential diagnosis should include a subchorionic haematoma, with a similar cystic-solid appearance and a mild trophoblast pathology of placental mesenchymal dysplasia co-existent with Beckwith-Wiedemann syndrome.⁶

Standard pathomorphologic assessment includes haematoxylin and eosin (H&E) staining and distinguishing the type of hydatidiform mole by morphology.⁹ In this reported case, from images and morphological examination of placenta diagnosis was partial mole with normal placenta. Histopathologically also diagnosed as partial molar changes with normal placenta. Immunohistochemical (IHC) staining for the protein p57Kip2, which is the product of the CDKN1C gene, is a reliable diagnostic tool in doubtful cases. As CDKN1C is paternally imprinted and maternally expressed, the p57Kip2 staining is absent in complete hydatidiform mole (CMH) which lacks a maternal genome. In case of partial molar pregnancy positive staining for p57Kip2.

Prenatal testing of the fetal karyotype is essential as it helps in deciding continuation and prognosis of the pregnancy.⁷ Termination of pregnancy is recommended in a triploid fetal karyotype and where as a diploid fetal karyotype is usually associated with a viable fetus with a normal placenta, co-existing along side a molar tissue, in which pregnancy can be continued with close monitoring.⁷ In this case, similar features were observed.

The co-existence of a molar pregnancy and a live normal fetus carries a risk of severe fetal and maternal complications. The most common maternal complications include severe hemorrhage, severe preeclampsia, hyperthyroidism and thromboembolic disorder.⁵ Some fetal growth retardation, intrauterine death, miscarriage or premature birth also reported.

In the past, the diagnosis of molar pregnancy with a co-existence live fetus was an indication for an immediate therapeutic termination. Now when, a normal fetal development is confirmed by USG and there are no maternal complications, ideally fetal karyotype is recommended, if possible.⁸ A conservative approach is possible under close monitoring, if no maternal complication arise.^{9,10,11} Women who decide to proceed with their pregnancy should be aware that the chance of a successful outcome are approximately 40%.^{9,10,11} Decreasing β HCG levels and absence of maternal complication are good predictors of a successful pregnancy outcome.¹³ In this reported case, β HCG level was decreasing from initial level.

The method of termination of these pregnancy needs to be carefully decided.² If the diagnosis is confirmed at first trimester, suction evacuation is the preferred method. When the diagnosis is confirmed in the second trimester, where the surgical evacuation has increased risk due to well-formed fetus.¹² The use of uterotonic is best avoided because the risk of trophoblastic embolization.¹¹ Medical termination is a viable alternative to surgical methods.¹³ In this reported case, spontaneous labor pain started at 36 weeks pregnancy and delivered a male baby without any complication per vaginally.

Conclusion

Pregnancy with hydatidiform molar changes and a coexisting live fetus requires a thorough evaluation and pregnancy may be continued under close surveillance. Monitoring of serum β HCG, serial USG for fetal growth and size of molar component can help to predict good outcome. Management of molar changes associated with normal appearing fetus still remains challenging as not many studies have been due to the rarity of this disorder. Close follow-up is necessary during and after gestation as to exclude persistent trophoblastic disease.

Conflict of Interest: There was no conflict of interest.

Funding: National Institute of Cancer Research and Hospital (NICRH), Dhaka, Bangladesh.

Ethical approval: Institutional Review Board of National Institute of Cancer Research and Hospital (NICRH), Dhaka, Bangladesh.

Submitted: 27 June 2022

Final revision received: 14 November 2022

Accepted: 20 November 2022

Published: 01 December 2022

Reference

1. Alokandana Roy, Sarita Kumari. A case report of twin pregnancy with Hydatidiform Mole and Co-existing Live Fetus. Saudi J Med Med Sci 2020; V 8:P 213-216. DOI:10.4103/sjmms.sjmms_332_19.
2. Rahamni M, Parviz S. A case report of partial molar pregnancy associated with a normal appearing dizygotic fetus. Asian Pac J reprod 2016; 5:171-173.
3. Farazestanian M, Maleki A, Bolandi S et al. Molar Changes With a Normal Viable Fetus: A case report. J Fam Reprod health 2020; 14:205-8. Available from: <http://jfrh.tums.ac.ir>
4. Nathani RS, Nisar Z. A Rare Case Report of Molar Pregnancy with Coexisting Fetus. Int J Recent Surg Med Sci 2018; 4:37-39.
5. Malgorzata G, Aleksandra Z, Mirosław W et al. Twin pregnancy with a partial hydatidiform mole and a coexistent live fetus. Diagnostic and therapeutic dilemmas. A case report and review of literature. Ginekologia Polska 2020; vol91; no10; 589-594. DOI: 10.5603/GP.a2020.0109.
6. Mohiuddin KM, Ratha C, satishrao I. Complete hydatidiform mole with a coexistent live fetus in a twin pregnancy. J Med Sci Res.2017; 5: 111-14. DOI: 10.17727/JMSR.2017/5-21.
7. Prathyusha K, Bhargavi N, Balasankar R. Persistent Invasive Mole: A case report. Ind jan Phar practice.2021; 14: 68-71. DOI:10.5530/ijopp.14.1.14.
8. Giorgione V, Cavoretto P, Cormio G et al. prenatal diagnosis of twin pregnancies with Complete hydatidiform Mole and Coexistent Normal fetus: a series of 13 cases. Gynecol obstet Invest. 2017; 82: 404-409. DOI: 10.1159/000448139
9. Freis A, Elsasser M, Sohn C et al. Twin pregnancy with one Fetus and One Complete mole-A Case Report. Geburtshilfe Frauenheilked. 2016; 76: 819-22. DOI: 10.1055/s-0042-109398
10. Ingec M, Borekci KG, Atlas S et al. Twin pregnancy with partial hydatidiform mole and coexistent normal fetus. J Obstet Gynaecol 2006;26: 379-80. DOI: 10.1080/01443610600618747
11. Peng HH, Huang KG, Chueh HY, et al. Term delivery of a complete hydatidiform mole with a coexisting living fetus followed by successful treatment of maternal metastatic gestational trophoblastic disease. Taiwan J Obstet Gynecol. 2014; 53: 397-400. DOI:10.1016/j.tjog.2013.02.005
12. Imafuku H, Miyahara Y, Ebina Y et al. ultrasound and MRI findings of Twin pregnancies with complete hydatidiform Mole and Coexisting Normal fetus: Two case reports. Kobe J Med Sci. 2018; 64:E1-E5, indexed in PubMed: 29375907.
13. Bristow RE, Shumway JB, Khouzami AN et al. Complete Hydatidiform mole and surviving coexisting twin. Obstet Gynecol surv.1996;51: 705-709. DOI: 10.1097/00006254-199612000-00002